

Article ▶ Multi-modality Optometric Treatment of Deep Amblyopia Secondary to Micro-esotropia and Anisometropia

Judy Cao, OD, Bellflower, California

Jana Giebel, OD, Pasadena, California

Derek Tong, OD, Pasadena, California

ABSTRACT

Background: Amblyopia is a reduction in visual acuity that often involves reduction in visual skills such as ocular motility and accommodation. Various treatment modalities for amblyopia include spectacle correction, patching, atropine, and optometric vision therapy (OVT). Clinically, OVT often reduces the severity of amblyopia. There is also considerable anecdotal evidence that improvement in amblyopia and its related visual deficiencies can be achieved at almost any age.

Case Report: A nine-year-old Caucasian male was referred by his primary care optometrist for amblyopia treatment. Previous treatment included full-time prescription lenses and part-time direct patching for 3½ years. Our evaluation found deep amblyopia secondary to anisometropia, micro-esotropia, and eccentric fixation. A visual evoked potential (VEP) was obtained to estimate his potential visual acuity and to rule out optic pathway defect. The SHAW lens, office-based vision therapy, home-based syntonics, and home-based Amblyopia iNet and Perceptual Visual Tracking programs were prescribed, and the patient continues to show good progress.

Conclusion: A multi-modality treatment approach provided a good functional outcome for this patient with deep amblyopia secondary to constant esotropia and anisometropia. The multi-modality treatment for this patient included spectacle lenses, as well as OVT and home-based vision therapy, for optimal results.

Keywords: amblyopia, anisometropia, eccentric fixation, esotropia, primitive reflexes, syntonics, vision therapy, visual vestibular

Background

Amblyopia is a unilateral, or occasionally bilateral, reduction in visual acuity worse than 20/20 with the patient's best correction in place.¹ It often involves reduced oculomotor skills, accommodative skills, monocular fixation, and contrast sensitivity. Amblyopia is usually caused by anisometropia, strabismus, or form deprivation. The degree of success in treating amblyopia with patching or atropine is often correlated with a patient's age and the severity of the amblyopia. One study showed that treatment of amblyopia for patients aged 3 to less than 7 years was more effective than treatment for patients aged 7 to less than 13 years.² Another study showed that treatment of amblyopia after 6 years of age was as effective as treating a patient under 6 years of age.³ The effect of amblyopia treatment was also more successful in moderate amblyopia (VA 20/40 to 20/100) than in severe amblyopia (VA 20/125 to 20/400).² Other research demonstrated that patching and atropine had similar effects in improving visual acuity in patients aged 7 to 12 years.⁴ Only one-fourth of amblyopic patients showed an increase in visual acuity with spectacle correction alone;⁴ therefore, further therapy is often needed to treat amblyopia. Studies have also illustrated that patients 7 to 17 years of age who were previously prescribed patching may not benefit from patching again.⁵ Therefore, optometric vision therapy (OVT) may be necessary in the

long-term treatment of the patient with deep amblyopia who previously received patching. Clinically, OVT often reduces the severity of amblyopia, which leads to improved binocularity.⁶ In fact, there is considerable evidence that improvement in amblyopia and its related visual deficiencies can be achieved at almost any age.

Case Report

History

NB, a 9-year-old Caucasian male in 3rd grade, was referred by his primary care optometrist for amblyopia treatment. At the initial evaluation, the patient reported reduced vision in his right eye and difficulty with reading. At the last eye examination with his primary care optometrist a year prior, NB was prescribed full-time single vision lenses as follows: OD +5.00-1.00x162 and OS +2.00 DS. NB had also been prescribed patching of his left eye for approximately 2 hours per day for the past 3½ years. The patient's developmental history was unremarkable. He was full-term with no complications during birth. When NB was six years old, he had an ear condition that required surgical insertion of ear tubes. Otherwise, he was reported to be in good health with no history of eye surgery or trauma. The patient had no history of allergies and was currently not on any medications. His family ocular and medical history was unremarkable.

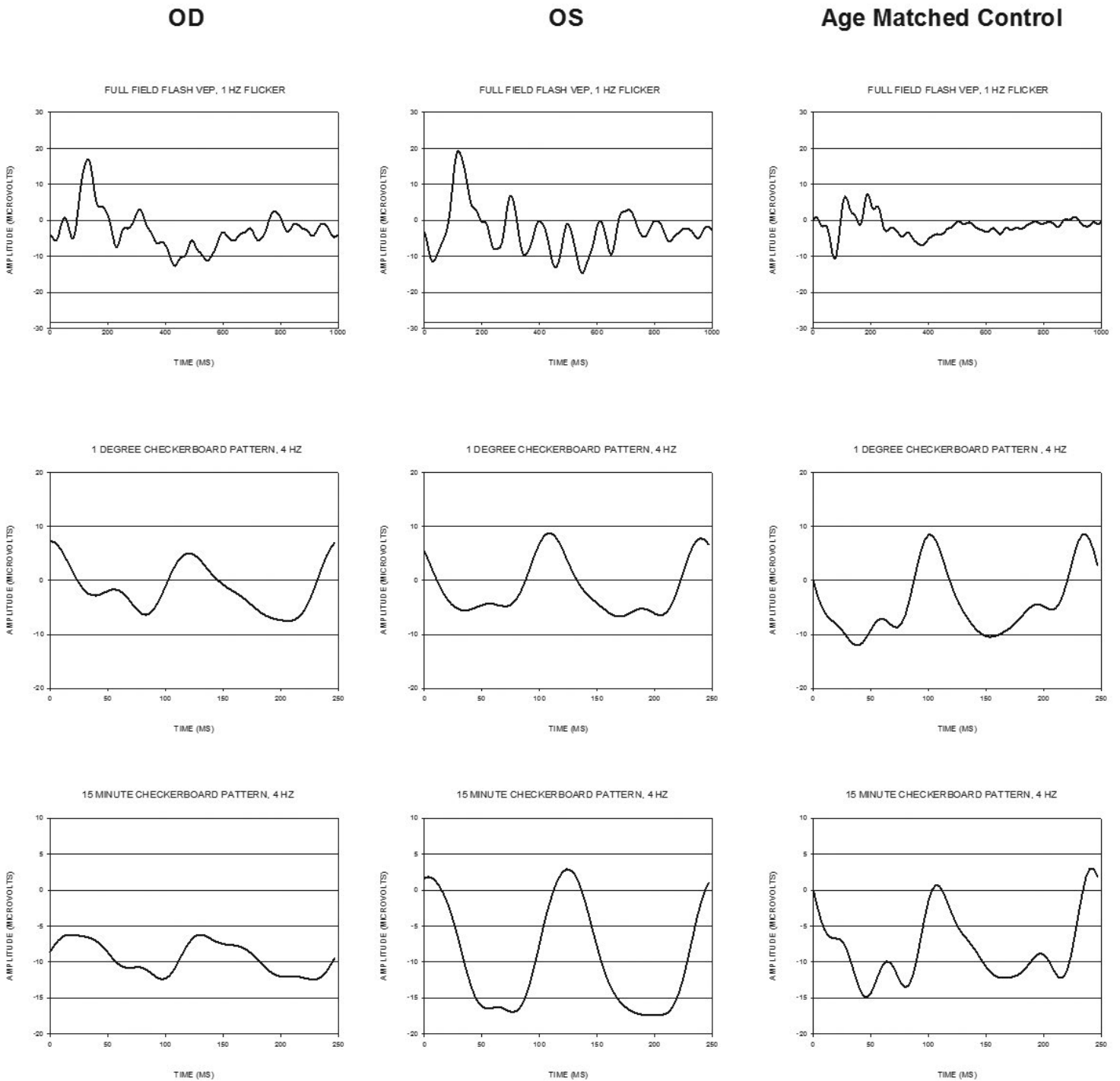


Figure 1. Flash VEP, 1-degree Pattern VEP, and 15-minute pattern VEP

the current status of the patient’s visual skills and to determine areas that required further improvement. Home-based vision therapy was also prescribed for approximately twenty minutes every day. Home therapy included syntonics, primitive reflex therapy, peripheral awareness activities, and computer-based vision therapy activities. At about vision therapy session #16, the patient reported a fall that resulted in a broken left arm. His mother reported more difficulty with tracking after the fall. The King-Devick test was performed, and tracking speed was recorded at 142 seconds with 2 errors. Previously, his tracking speed was 69 seconds with 2 errors. Therefore, additional

oculomotor activities were prescribed during in-office vision therapy, and Perceptual Visual Tracking was assigned for home vision therapy.

Vision Therapy

The specific vision therapy activities performed to enhance the patient’s visual skills are listed in Table 2. Binocular vision therapy activities were incorporated to establish binocularity and to reduce suppression in the right eye. The quoit vectogram was performed but with intermittent binocularity. The patient’s visual localization of



Figure 2. SHAW Lens™

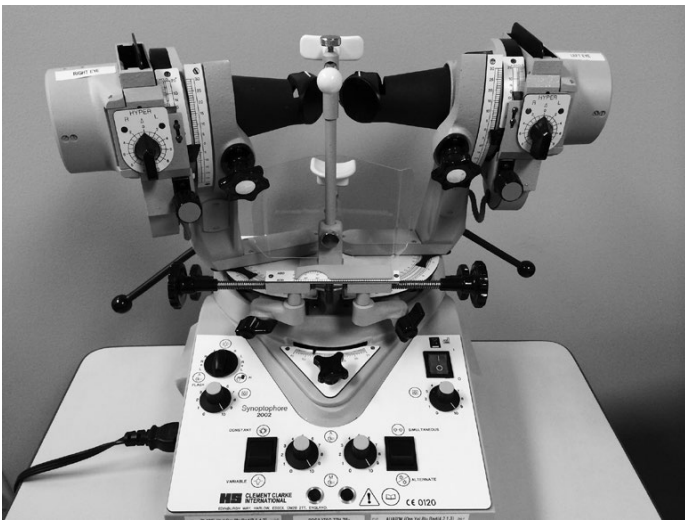


Figure 3. Major amblyscope (Synoptophore)

the target was unsteady, and responses alternated between SILO and SOLI. The patient's degree of suppression of the right eye varied during each session; therefore, other anti-suppression therapies were performed. Monocular fixation in a binocular field (MFBF) with the 8.5" x 11" Goth Torgerson Vision Therapy (GTVT) chart and the Sanet Vision Integrator (SVI) was performed, with the red patch over the left eye to reduce suppression. Red-green anti-suppression activities were also performed, and over time, the patient's fusional ranges gradually increased. The major amblyscope (Figure 3) with the Flom swing (Figure 4) was used during therapy to increase divergence amplitude, stability, and depth perception. The patient reported left-to-right motion of the swing. VTS-4 was also performed to increase vergence ranges, with an emphasis on base-in ranges. Brock string was incorporated to further improve his vergence skills.

Oculomotor therapy activities began with gross saccades using the space fixator. Bilateral integration was incorporated into the oculomotor therapy with alternating hands as well as ipsilateral and contralateral movements. A metronome was added in order to integrate auditory processing, rhythm, timing, and speed with visual processing. Pursuits and saccades were done monocularly in a binocular field using the 8.5" x 11" GTVT chart. Two red-green Bernell sticks were held approximately 10" apart and about three feet away while the patient performed saccadic eye movements from one



Figure 4. Flom swing

Bernell stick to the other. The SVI was also used to enhance saccadic skills.

Monocular fixation therapy with the macular integrity tester (MIT) was performed to minimize, and hopefully to eliminate, eccentric fixation in the right eye. The patient was able to place the offset Haidinger brush on the target with effort. After a few sessions, the patient was not able to perceive the Haidinger brush; therefore, this technique was discontinued.

Accommodative therapy included Zone-Trac, which provided the patient with biofeedback by measuring the alpha brain waves (which are generally thought to be a representation of the accommodative function of the patient's eyes) and converting these signals into a high- or low-pitch sound. Optimally, the goal is for the patient to alter his accommodative response in order to elicit the highest-pitch sound. NB was ultimately able to elicit the highest-pitch sound by attempting to focus harder while being aware of his periphery. Minus lens rock was also incorporated to improve NB's accommodative skills further.

Visual-vestibular activities were incorporated before each major vision therapy task for approximately 1 to 2 minutes. Each vision therapy session included three main vision therapy activities, each lasting approximately fifteen minutes. Several visual-vestibular activities performed with the patient are listed in Table 2. Visual-vestibular activities were incorporated to stimulate the vestibular system, which sends signals to the extraocular muscles to increase function and progress of the visual system during therapy.⁷ One study has shown that vestibular hypofunction can result in oculomotor dysfunction, leading to difficulties with reading.⁸

Home-based vision therapy activities are listed in Table 3. Home-based therapy began with syntonics. Syntonics is a light-based therapy that is performed for twenty minutes per day for about four weeks.⁹ During the evaluation, it was noted that the patient had retained primitive reflexes, and

Table 2. In-Office Optometric Vision Therapy Activities

Binocular/Anti-suppression	Oculomotor	Monocular Fixation	Visual-Vestibular	Accommodative
Vectogram	Space fixator	Macular Integrity Tester (MIT)	Trampoline and bean bag toss	Zone-Trac
R/G luster with white board	MFBF with GTVT chart 8.5"x11" and SVI (red patch OS)		Trampoline and Hart chart	Minus lens rock
R/G Pediatric Flashlight (PFL)	R/G Bernell sticks (saccades)		Therapy ball and Hart chart	
R/G tranaglyph	Sanet Vision Integrator (SVI)		Mirror eye stretch (emphasis on right gaze)	
R/G Maze with Flashlight and red acetate (red glasses OD)				
R/G Maze with Green marker				
R/G with SVI				
MFBF with GTVT chart 8.5"x11" and SVI (red patch OS)				
Major amblyoscope (Flom swing)				
VTS-4				
Brock string				

Table 3. Home-Based Vision Therapy Activities

Light therapy	Primitive reflexes	Peripheral awareness	Computer-based program
Syntonics (red-orange, lemon)	Toes in/out	ET touch	AiNet
	Superman	VO Star chart	PVT
		Sherman Numbers chart	
		Lora Card	

therefore specific home therapy activities were prescribed to integrate the primitive reflexes. Retained primitive reflexes can make it difficult for patients to have appropriate gross motor control, which hinders the optimal movement of fine extraocular muscles.¹⁰ The primitive reflex therapies for this patient included toes-in walk with thumbs out and toes-out walk with thumbs in to work on the moro reflex. The other primitive reflex activity assigned was Superman, which works on the tonic labyrinth reflex (TLR). For Superman, the patient lies in the prone position and lifts only his upper body and arms while fixating on a target straight ahead. While working on integrating the moro reflex and the TLR, this seems to have assisted in integrating the ATNR and HRR as well, therefore no further therapies were programmed to integrate the asymmetrical tonic neck reflex (ATNR) and head retraction reflex (HRR). Peripheral awareness activities were also incorporated. AiNet and PVT are computer-based vision therapy programs that the patient performed at home

to increase the visual input to the patient's right eye and to enhance oculomotor skills, respectively. PVT was incorporated into the home therapy program after the patient suffered a fall, as detailed above.

Outcome

After performing a primary care eye examination with dilated fundus examination and cycloplegic refraction following vision therapy session #57, an updated SHAW lens prescription was ordered in single vision polycarbonate lenses: OD +3.50-1.25x170 and OS +2.00 DS. During the final progress evaluation at session #60, the patient's visual acuity improved in the right eye from 20/150 to 20/70⁻¹, and his constant right esotropia reduced to orthophoria at distance and 2 to 4^Δ esophoria at near. The SCCO test revealed improvement in pursuits and saccades to normative levels. The King-Devick test showed an increase in oculomotor speed to age-appropriate norms. Worth 4-Dot testing improved from constant suppression of the right eye to grade A fusion from 16 inches to 20 feet. American Optical campimetry showed an expansion of peripheral fields in both eyes. Primitive reflex testing showed a reduction in retained primitive reflexes. Stereopsis testing improved from none to 200 seconds of arc lateral disparity and 500 seconds of arc random dot stereopsis. Phorometry testing initially showed suppression and improved to base-out blur, break, and recovery of x/20/8. Table 1 provides an overview of the findings pre- and post-therapy. NB reported improved grades, greater enjoyment of reading, and improved reading comprehension. Both NB and his family were extremely happy with his progress during vision therapy. NB graduated from vision therapy at session #60 and will be monitored with post-VT progress evaluations.

Follow-up Care

NB was scheduled to have 1-month, 3-month, and 6-month post-vision therapy progress evaluations to ensure the retention of his improved visual skills. He was recommended to continue the AiNet computer program 1 to 2 times per week.

At NB's 1-month post-VT progress evaluation, NB reported falling during a school field trip 2 1/2 weeks prior with no bleeding, loss of consciousness, or alternation of consciousness. There were no symptoms of blur, headaches, diplopia, pain, flashes of light, or floaters. Distance visual acuity was OD 20/80 (20/60 isolated letter) and OS 20/20. Near visual acuity was OD 20/100 and OS 20/20. Cover test at distance and near revealed 4^Δ constant right esotropia and 8 to 10^Δ constant right esotropia, respectively. Base-out and base-in ranges for distance and near revealed suppression. There was no Random dot or lateral disparity stereopsis. King-Devick test was 1 error (normal) and 54 seconds (normal). The 4 Base-out test was positive. Worth 4-Dot test revealed grade A fusion at distance (20 ft) and near (16 inches). The Bagolini test showed an "X," and unilateral cover test showed

outward movements. Visual Midline Shift Syndrome (VMSS) testing showed no VMSS. Slit lamp examination, intraocular pressure with non-contact tonometry (13 mm Hg OD, OS), and undilated 90D Volk lens ophthalmoscopy were normal OU. The recommendation was to follow up in two months and to return as soon as possible if vision worsened or there was an increase in pain or flashes/floaters.

At the 3-month post-vision therapy progress evaluation, NB reported no vision symptoms and indicated that he had been reading quicker and easier. Distance visual acuity was OD 20/80 and OS 20/20. Near visual acuity was OD 20/200^{+1/2} and OS 20/20. Cover test showed orthophoria at distance and 6^Δ intermittent right esotropia at near. Prism bar vergences were base out 14/1 and base in 25/0 at distance, base out 14/10 and base in 18/12 at near. He also showed 400" of lateral disparity stereopsis and 500" random dot stereopsis on 1 of the 3 targets in the Randot Stereo Test. The 4 Base-out test was positive. Worth 4-Dot testing revealed grade A fusion at distance (20 ft) and near (16 inches). Bagolini test showed an "X," and unilateral cover test showed outward movements only 1 out of 4 times. He was recommended to return in 3 months for the next progress evaluation.

Conclusion

A multi-modality treatment approach may be needed in order to achieve the highest success in patients with deep amblyopia secondary to constant esotropia and anisometropia. The multi-modality treatment for this patient included prescribing SHAW lenses for the anisometropia and OVT for the amblyopia and strabismus. A combination of in-office and home-based vision therapy is recommended for optimal results. OVT in this case included activities that enhanced ocular motility and binocularity through anti-suppression techniques and increased vergence ranges and also incorporated visual-vestibular integration. Home-based vision therapy included syntonics, primitive reflex integration, and the AiNet and PVT computer programs. Through this multi-modality treatment, the patient showed improvement in visual acuity as well as increased binocularity and oculomotor skills.

Acknowledgement

The authors would like to thank Dr. William Ridder III, OD, PhD of the Southern California College of Optometry at Marshall B. Ketchum University for performing the Visual Evoked Potential and providing the graphs.

References

1. Rouse M, et al. Care of the patient with amblyopia. Optometric clinical practice guideline. AOA. 1994:1-31.
2. Holmes J, et al. Effect of age on response to amblyopia treatment in children. Arch Ophthalmol 2011;129(11):1451-7.
3. Birnbaum M, et al. Success in amblyopia as a function of age: A literature survey. Am J Optom Physiol Opt 1977;54(5):269-75.
4. Scheiman MM, et al. Patching vs atropine to treat amblyopia in children aged 7 to 12 years: A randomized trial. Arch Ophthalmol 2008;126(12):1634-42.
5. Pediatric Eye Disease Investigator Group. Randomized trial of treatment of amblyopia in children aged 7 to 17 years. Arch Ophthalmol 2005;123(4):437-47.
6. FitzGerald DE, Krumholtz I. Maintenance of improvement gains in refractive amblyopia: A comparison of treatment modalities. J Am Optom Assoc 2002;73(3):153-9.
7. Przekoracka-Krawczyk A, et al. Impaired body balance control in adults with strabismus. Vision Res 2014;98:35-45.
8. Braswell J, Rine RM. Evidence that vestibular hypofunction affects reading acuity in children. Int J Pediatr Otorhinolaryngol 2006;70(11):1957-65.
9. Gottlieb R, Wallace L. Syntonic Phototherapy. J Behav Optom 2001;12(2):31-8.
10. Goddard S. The role of primitive survival reflexes in the development of the visual system. J Behav Optom 1995;6(2):31-5.

Correspondence regarding this article should be emailed to Judy Cao, OD, at judycao@ymail.com. All statements are the authors' personal opinions and may not reflect the opinions of the representative organizations, ACBO or OEPE, Optometry & Visual Performance, or any institution or organization with which the authors may be affiliated. Permission to use reprints of this article must be obtained from the editor. Copyright 2017 Optometric Extension Program Foundation. Online access is available at www.acbo.org.au, www.oepf.org, and www.ovpjjournal.org.

Cao J, Giebel J, Tong D. Multi-modality optometric treatment of deep amblyopia secondary to micro-esotropia and anisometropia. Optom Vis Perf 2017;5(3):97-102.

***The online version of this article
contains digital enhancements.***